

## A 53-year-old female with bladder leiomyoma: A rare case and review of the literature

Benign bladder diseases

Aydemir Asdemir<sup>1</sup>, Tugba Yildiz Asdemir<sup>2</sup>, Huseyin Saygin<sup>3</sup>, Esat Korgali<sup>3</sup>, Resul Cicek<sup>4</sup><sup>1</sup>Urology Clinic, Suluova Public Hospital, Amasya<sup>2</sup>Department of Old Care, Sabuncuoglu Serefeddin Vocational School Of Health Services , Amasya University, Amasya<sup>3</sup>Department of Urology, Faculty of Medicine, Cumhuriyet University, Sivas<sup>4</sup>Urology Clinic, Malatya Training And Research Hospital, , Malatya, Turkey

*This article's abstract was presented on 26. Congress of National Urology and on 5. Congress of Urologic Surgery.*

### Abstract

Leiomyoma as a benign tumor of the urinary bladder, is uncommon and usually presents with obstructive voiding symptoms or irritative urinary symptoms. A 53-year-old woman was hospitalized to the general surgery clinic due to abdominal pain. During her contrast-enhanced computed tomography (CT) examination, incidentally, a mass on the left anterosuperolateral side of the bladder wall was revealed. No significant finding was detected on physical examination. There was only microscopic hematuria as a result of urinalysis. Contrast-enhanced CT confirmed the presence of a mass on the left anterosuperolateral side of the bladder wall without evidence of extravesical extension and showed a well-delineated 2,6 cm x 2,4 cm endovesical bladder tumor arising from the left anterosuperolateral bladder wall and there was a thickening of the urinary bladder wall. On cystoscopy, an intraluminally protruding, rounded, smooth, sessile solid mass, 2,5 cm in diameter and covered by normal bladder mucosa, was seen. She underwent an uneventful transurethral resection of bladder tumor (TURBT) and histological examination revealed intersecting fascicles of smooth muscle without any evidence of malignant change, and thus diagnosis of leiomyoma was confirmed. Confirmation of the diagnosis may be difficult due to the poor yield of cold cup biopsy. In our case, transurethral resection (TUR) was diagnostic.

### Keywords

Leiomyoma; Bladder; Benign

DOI: 10.4328/ACAM.20480 Received: 2021-01-12 Accepted: 2021-02-11 Published Online: 2021-02-23 Printed: 2021-08-01 Ann Clin Anal Med 2021;12(8):947-950

Corresponding Author: Aydemir Asdemir, Urology Clinic, Suluova Public Hospital, 05500, Amasya, Turkey.

E-mail: aydemirasdemir@hotmail.com P: +90 5068943216

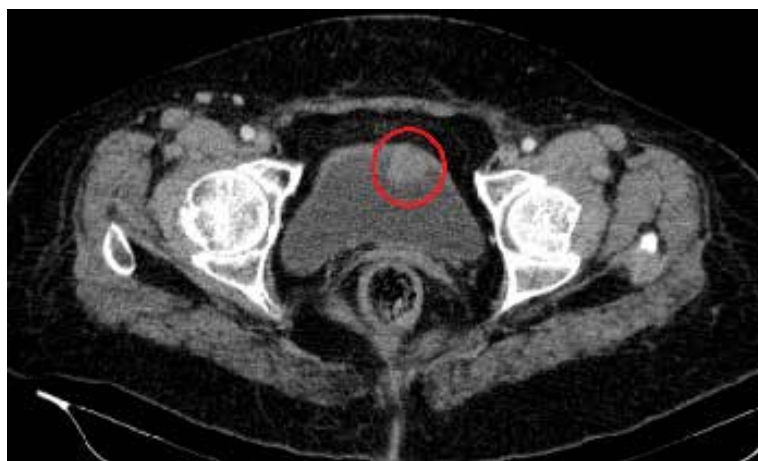Corresponding Author ORCID ID: <https://orcid.org/0000-0002-9141-6727>

## Introduction

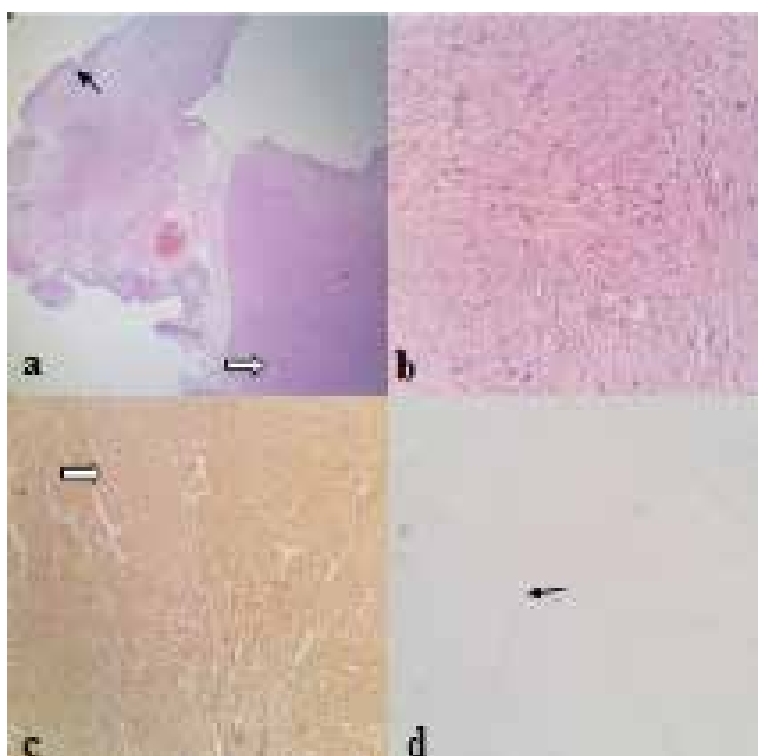
Leiomyoma, as a benign tumor of the urinary bladder, is uncommon and usually presents with obstructive voiding symptoms or irritative urinary symptoms. [1] But several previous cases had involved dyspareunia symptoms. [2] Although bladder tumors are one of the most common malignancies worldwide (Chou R, et al. Treatment of muscle-invasive bladder cancer: a systematic review. *Cancer* 2016) leiomyoma accounts only for <0.5% of all bladder cancers. [3, 4]

## Case Report

A 53-year-old female who had a history of total abdominal hysterectomy and bilateral salpingo-oophorectomy 15 years ago was hospitalized to the general surgery clinic due to abdominal pain. During her contrast-enhanced CT examination, incidentally, a mass on the left anterosuperolateral side of the bladder wall was revealed. The patient was referred to the urologist examination; however, there were no symptoms, including dysuria, urgency, nocturia, incontinence, pollakiuria, macroscopic hematuria, and obstructive complaints. No significant findings were detected on physical examination. Urinary tract infection was excluded and there was only microscopic hematuria as a result of urinalysis. The results of other laboratory tests, including renal function, liver function, complete blood cell count, and coagulation function were also within the normal range. Contrast-enhanced CT confirmed the presence of a mass on the left anterosuperolateral side of the bladder wall without evidence of extravesical extension and showed a well-delineated endovesical bladder tumor measuring 2,6 cm × 2.4 cm, arising from the left anterosuperolateral bladder wall and there was a thickening of the urinary bladder wall (Figure 1). There was no evidence of locoregional invasion. The upper urinary tract was functionally and structurally normal. On cystoscopy, an intraluminally protruding, rounded, smooth, sessile solid mass, 2,5 cm in diameter and covered by normal bladder mucosa, was seen. She underwent an uneventful TURBT, and histological examination revealed intersecting fascicles of smooth muscle (Figure 2a, b) without any evidence of malignant changes, and thus diagnosis of leiomyoma was confirmed. Microscopically, the bladder tissue covered with transitional epithelium (black arrow) was observed. Smooth muscle cells in the form of fascicles were observed under the epithelium, which formed a solid mass (white arrow) (Figure 2a). All the fragments showed the same view composed of spindle cells and fibers arranged in fascicles, separated by scant hyaline stroma (Figure 2a). The nuclei of the cells were cigar-shaped and centrally located. There was no evidence of atypia, necrosis, or mitosis (Figure 2b). The spindle cells demonstrated a smooth-muscle differentiation by positive staining with SMA (actin-smooth-muscle) (white arrow) (Figure 2c) but they are negative for Ki-67 (around 1%, black arrow) (Figure 2d). The tumor tissues were fixed in formalin, paraffin-embedded, and 5-mm-thick cut and stained with hematoxylin and eosin; immunostains for SMA, Ki67 were performed using the avidin-biotin-peroxidase complex method. The postoperative period was uneventful, the urinary catheter was removed after 3 days and the patient was discharged on postoperative day 5.



**Figure 1.** CT view of the intraluminal polypoidal enhancing mass projecting into the bladder lumen



**Figure 2.** Pathological specimen

- a: Haematoxylin and eosin, x40
- b: Haematoxylin and eosin, x200
- c: Smooth muscle actin, x200
- d: Ki 67, x100

## Discussion

Leiomyoma is a benign smooth muscle tumor that can occur in any organ, but is most often seen in the uterus. [5] Leiomyomas of the bladder are rare benign tumors. [6] Goluboff et al. [7] reviewed all related literature and indicated that the most common symptoms for urinary leiomyoma were obstructive voiding symptoms (49%). Among the remaining patients, 38% presented with irritative symptoms, 11% with hematuria, and 19% were asymptomatic. However, Knoll et al. (Leiomyoma of the bladder. *J Urol* 1986) reviewed the literature and indicated that the most frequent clinical manifestations were irritative

voiding symptoms. It was suggested that leiomyoma of the bladder is symptomatic for 2 reasons: anatomical location and size. Specifically, tumors that are present at ureteral openings or near the bladder neck tend to cause obstructive symptoms, whereas larger tumors are more likely to cause irritative symptoms. Neither of our patients had any positive findings on physical examination, although one series in the literature reported on a palpable pelvic lump in approximately 50% of patients on bimanual examination. [7] In the urinary system, the location is more frequent in the bladder, being the most common benign mesenchymal tumor of this organ (Tavora F, et al. Mesenchymal tumours of the bladder and prostate: an update. *Pathology* 2013). Nonetheless, they only represent <0.5% of all bladder cancers. [3, 4] Virchow first reported this in 1931 (JL K. Leiomyoma of the bladder with a report of a case and a review of the literature. *J Urol* 1931). In a review by Khater and Sakr in 2013, only 250 cases were previously reported, and since then rare cases have been reported. [3, 5, 6, 8] There is a female preponderance (70%), and this pathology affects those in their third to sixth decades, with a mean age of 44 years. [3, 7, 8] However, there are cases described in younger patients. These tumors can be endovesical, intramural, or extravescical. The endovesical tumors are the most common and usually present with dysuria, urinary urgency, hematuria, and sometimes with low back pain. Some tumors are pedunculated and can manifest through urinary retention. [1, 4] Regarding the diagnosis, bladder ultrasound is the imagiological examination that detects more often these tumors. In most cases, it shows a small mass with a solid aspect, homogeneous, and hypoechoic encapsulated by a hyperechogenic thin blade. [3] Cystoscopy shows the presence of a sessile tumor not arborescent and protruding into the bladder lumen. Computed tomography and magnetic resonance imaging (MRI) can be performed to obtain further information on the size and location. [8] Even though both CT and MRI offer excellent delineation of the tumor, Wong and colleagues opined that MRI should be the method of choice as it offers superior contrast and spatial resolution (Wong FK, et al. Urinary bladder leiomyoma. *J HK Coll Radiol*. 2002). Leiomyomas are known to show a variety of tumor-enhancement patterns after gadolinium injection but cystic degeneration always produces heterogeneous signal intensity on T2-weighted and post-gadolinium T1-weighted images (Chen M, et al. MR imaging evaluation of benign mesenchymal tumors of the urinary bladder. *AJR Am J Roentgenol*. 1998). MRI is the preferred method for the composition and relation to plans of the bladder wall. Despite the imaging characteristic features, the definitive diagnosis is histopathology. [4] The treatment of leiomyoma is surgical, and the approach depends on the location and size of the tumor. A small tumor in an asymptomatic patient may be treated conservatively with regular follow-up. An increase in size or the onset of symptoms merits surgery. In most cases, the transurethral route is preferred although some tumors, such as larger tumors involving the entire bladder wall, in a not propitious position or difficult to recognize, may require segmental resection or laparoscopic partial cystectomy. [3, 7] Enucleation via a transvaginal approach is another option, especially for tumors close to the urethra, but this is subject to anatomic constraints and a higher risk of recurrence (Knoll

LD, et al. Leiomyoma of the bladder. *J Urol*. 1986). Surgical complications are described almost exclusively in the larger urethral tumors. The prognosis is invariably favorable, with relief of complaints in symptomatic patients. The recurrence is rare. [4] Immunohistochemical and pathologic findings of bladder leiomyomas are similar to uterine leiomyomas (Jain SK, et al. Bladder leiomyoma presenting with LUTS and coexisting bladder and uterine leiomyomata: A review of two cases. *Rev Urol*. 2014). The precise etiology of this epidemiologic observation remains a mystery. However, it has been reported that estrogen may be associated with the growth of leiomyomas. [6] It was suggested that estrogen may influence the development of bladder leiomyoma. In addition, estrogen receptors have been identified in urinary leiomyomas. [1, 7] Many theories exist on the etiology of this condition and the reason for its predominance in women. It has been suggested that chromosomal abnormalities (Cornella JL, et al. Leiomyoma of the female urethra and bladder: report of twentythree patients and review of the literature. *Am J Obstet Gynecol*. 1997), chronic inflammatory stimuli (Blum's irritative theory), metaplastic reaction around the perivascular walls following inflammation of the bladder, dysontogenesis of embryonic rests (Piegel), or endocrine disorders (Lipschutz) may lead to the genesis of leiomyomas. [7] The latter theory is supported by observations of a higher incidence in women in the fertile period and the presence of steroidal ovarian receptors in the tumor (Furuhashi M, et al. Recurrent bladder leiomyoma with ovarian steroid hormone receptors. *J Urol*. 2002). Further work is needed to clarify the concrete mechanism that can lead to the initiation of bladder leiomyoma. For histologic diagnosis, tissue samples have been procured by a variety of means, including cup biopsy forceps, a resectoscope, or an ultrasound-guided transvaginal biopsy (Matsushima M, et al. Leiomyoma of the bladder presenting as acute urinary retention in a female patient: urodynamic analysis of lower urinary tract symptoms: a case report. *BMC Urol*. 2010). Microscopically, bladder leiomyomas are composed of interlacing and whorling bundles of smooth muscle cells. The nuclei of smooth muscle cells are oval to cigar-shaped, blunt-ended, centrally located and showing no nuclear atypia or mitotic activity. [1] Bladder leiomyoma usually has fewer than 2 mitotic figures per high power field. [7] Leiomyosarcoma, on the other hand, may also have few mitotic figures, but it is myxoid degeneration and invasion of the muscularis propria that reliably distinguishes it from the benign counterpart. Immunohistochemistry analysis of benign leiomyoma shows positive expression for smooth muscle actin and negative expression for Ki-67. The prognosis for these benign tumors is excellent and no cases of malignant degeneration have yet to be reported. [2]

### Conclusion

Leiomyoma must be differentiated from other common causes of lower urinary tract symptoms (LUTS). Confirmation of diagnosis may be difficult due to the poor yield of a cold cup biopsy. In our case, TUR was diagnostic. When the bladder TUR biopsies were clinically mentioned, in the presence of a thicker muscle layer than the detrusor muscle tissue, leiomyomas should be present in the differential diagnosis.

#### **Scientific Responsibility Statement**

The authors declare that they are responsible for the article's scientific content including study design, data collection, analysis and interpretation, writing, some of the main line, or all of the preparation and scientific review of the contents and approval of the final version of the article.

#### **Animal and human rights statement**

All procedures performed in this study were in accordance with the ethical standards of the institutional and/or national research committee and with the 1964 Helsinki declaration and its later amendments or comparable ethical standards. No animal or human studies were carried out by the authors for this article.

#### **Conflict of interest**

None of the authors received any type of financial support that could be considered potential conflict of interest regarding the manuscript or its submission.

#### **References**

1. Dewaele T, D'Hooghe L, Weyers St, Visschere P De. Leiomyoma of the urinary bladder. *JBR-BTR* 2014; 97:263.
2. Kim IY, Sadeghi F, Slawin KM. Dyspareunia: an unusual presentation of leiomyoma of the bladder. *Rev Urol* 2001; 3:152–54.
3. Khater N, Sakr G. Bladder leiomyoma: Presentation, evaluation and treatment. *Arab J Urol.* 2013;11:54–61.
4. Pardal H, Ferronha F, Gameiro C, Vilas-Boas V, Galego P, Melo P, et al. Intramural vesical leiomyoma in a patient with a pelvic fibrous tumour - case report. *Acta Urol.* 2011;2:28–31.
5. Xin J, Lai HP, Lin SK, Zhang QQ, Shao CX, Jin L, et al. Bladder leiomyoma presenting as dyspareunia: Case report and literature review. *Medicine (Baltimore)* 2016;95:e3971.
6. Wu S. Imaging findings of atypical leiomyoma of the urinary bladder simulating bladder cancer: a case report and literature review. *Med Ultrason* 2013; 15:161–3.
7. Goluboff ET, O'Toole K, Sawczuk IS. Leiomyoma of bladder: report of case and review of literature. *Urology* 1994; 43:238–41.
8. Silva-Gutiérrez A, Martínez-Méndez ME, González-Romo MA, Nava-Jácome O, Castillo-Zurita O, Morales-Díaz J, et al. Bladder leiomyoma. *Rev Mex Urol.* 2013;73:43–5.

#### **How to cite this article:**

Aydemir Asdemir, Tugba Yildiz Asdemir, Huseyin Saygin, Esat Korgali, Resul Cicek. A 53-year-old female with bladder leiomyoma: A rare case and review of the literature. *Ann Clin Anal Med* 2021;12(8):947-950